



Case Report

HYPERSENSITIVITY VASCULITIS WITH ACUTE NEPHRITIC SYNDROME DURING SEVERE CO-INFECTION

E. Kostadinova^{1*}, V. Tzaneva²

¹Department of Pediatrics, University Hospital, Medical Faculty, Trakia University, Stara Zagora

²Department of Epidemiology and Infectious Diseases, Medical Faculty, Trakia University, Stara Zagora, Bulgaria

ABSTRACT

Many pathogenic microorganisms can induce a complex series of immunologic, endothelial-cell and cascades activation and dysfunctions. These events induce the development of hypersensitivity vasculitis. Case report: We report the case of 13 years-old girl with hypersensitivity vasculitis, which developed during the course of a mixed infection with beta-hemolytic streptococcus and EBV infection. A month before hospitalization the girl had two episodes of purulent tonsillitis for which she received antibiotic treatment. After a week period without complains she is presented again with high temperature, chills, photophobia, insomnia, muscle pains, maculopapular rash that involves the body and suppurative tonsillitis. In the next days haemorrhagic macules, papules and patches appeared on the face, neck, legs, bilateral conjunctival ecchymosis, epistaxis and tonsillar hemorrhage. The medical condition manifests with deteriorated condition of the child, septic fever, generalized lymphadenopathy and hepatosplenomegaly. The clinical presentation is enriched with symptoms of acute nephritic syndrome. There is a history of several tick bites and contact with dogs, without clinical evidence for Erythema migrans. Conclusions: This case is a demonstration of a severe clinical course of Hypersensitivity vasculitis with acute nephritic syndrome as a result of the identified co-infection beta-hemolytic streptococcus and EBV infection. The clinical course is due to the development of complicated pathogenic and immunologic mechanisms. The positive serology for B. Burgdorferi without the presentation of the specific symptoms of Lyme disease is due to cross reaction. Long-term clinical and laboratory follow-up showed complete recovery.

Key words: hypersensitivity vasculitis, acute nephritic syndrome, co-infection beta-hemolytic streptococcus and EBV infection.

INTRODUCTION

Many pathogenic microorganisms can induce a complex series of immunologic, endothelial-cell and cascades activation and dysfunctions. These events induce interactions of various components of the vessel wall which lead to the development of hypersensitivity vasculitis.(1) Hypersensitivity vasculitis refers to vasculitis affecting small- or medium-sized vessels in the skin and subcutaneous tissue.(2) The internal organs most commonly affected in hypersensitivity vasculitis are the joints, gastrointestinal tract, and kidneys.(3) The prognosis of hypersensitivity vasculitis depends on the presence or absence of involvement of internal organs.

CASE REPORT

We report the case of 13 years-old girl, previously healthy and without family history for kidney abnormalities.

A month prior to hospitalization the girl had two episodes of purulent tonsillitis for which she received Augmentin. After a week period without complains, she is presented again with high temperature, chills, photophobia, insomnia, muscle pains, maculopapular rash that involves the body and suppurative tonsillitis. The girl was treated at home with Ceroxim and Gentamycin for five days without effect. In the next days hemorrhagic macules, papules and patches appeared on the face, neck, legs and upper limbs. (**Figure 1**), bilateral conjunctival ecchymosis (**Figure 2**), eyelids haematomas, epistaxis and tonsillar hemorrhage.

*Correspondence to: Emilia Kostadinova
Pediatric Clinic, University Hospital, Stara Zagora,
Bulgaria, kostadinovaemilia@abv.bg

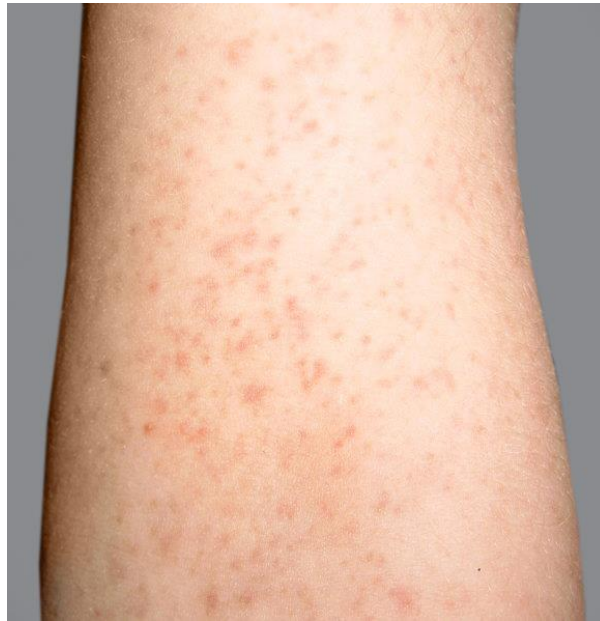

Figure 1. Haemorrhagic rash on upper limb



Figure 2. Oedematous and turgescence facies, conjunctival ecchymosis and eyelids haematomas

The medical condition manifests with deteriorated condition of the child, septic fever for 5 days, oedematous and turgescence facies, generalized lymphadenopathy and significant hepatosplenomegaly. The liver and spleen are palpated 3 cm below the rib arch with an elastic consistency, painless. On admission to the clinic the child was without clinical evidence of pneumonia, with BP 26/min, HR 110/min, BP 115/70. The clinical presentation is enriched with breathing difficulty, coughing and orthopnoic position, arterial hypertension up to 160/110 mm Hg, macroscopic haematuria, moderate proteinuria, oliguria(0,5ml/kg/h) and acute renal failure which symptoms are in the context of acute nephritic syndrome. There is a history for several tick bites and a contact with

dogs, without clinical evidence for Erythema migrans.

After a wide range of differential diagnoses were discussed, the diagnosis: Hypersensitivity vasculitis with acute nephritic syndrome was based on the clinical presentation and extensive screening of haematological, serological, microbiological and immunological tests. The ethio-pathogenic role of the preceding streptococcal infection and active EBV infection was verified.

The diagnosis is supported by the following findings:

- moderate inflammatory activity (CRP-36 mg/l)
- erythrocyte sedimentation rate of 50 mm.

- mild normochromic normocytic anaemia (Hb-102 g/l, Hct-0,30),
- white blood cell count of $16,6 \cdot 10^9$ g/l, lymphomonocytosis and leucocytes with plasmatisation;
- mild hepatic injury (ASAT-58U/l, ALAT-63U/l, γ GTP-114U/l)
- creatinine clearance of 59ml/min./1,73 m², creatinine level of 121μ /mmol/l, blood urea nitrogen-10,12mmol/l, uric acid- 532μ mmol/l, K-6,15 mmol/l, Na-127,5 mmol/l, P-1.45mmol/l),
- hypocomplementemia - C₃-0,66g/l (reference 0,9 – 1,8 g/l), C₄<0,075 g/l(reference 0,1 – 0, 4 g/l),
- elevated levels of Ig G-16,26 g/l (reference 7.59 – 15.50)

- AST- marked elevation of 1600 ASE
- anti EBV VCA Ig M(+) 68,2
- anti B.burgdorferi IgM (+) 36,8; (+) 25,04
- anti B.burgdorferi IgG (+); (-),
- macro/microscopic hematuria, moderate proteinuria of 1,07g/l
- pharyngeal swab – β hemolytic streptococcus,
- chest radiography – increased lung markings, marked right interlobe, enlarged hilar shadows bilaterally
- abdominal ultrasound – marked hepatosplenomegaly, enlarged kidneys with increased echogenicity of parenchyma, edematous parenchyma, small amount of ascitic fluid, bilateral pleural effusion. Doppler sonography of renal artery –normal blood flow in the two renal arteries (**Figure 3a, b**).

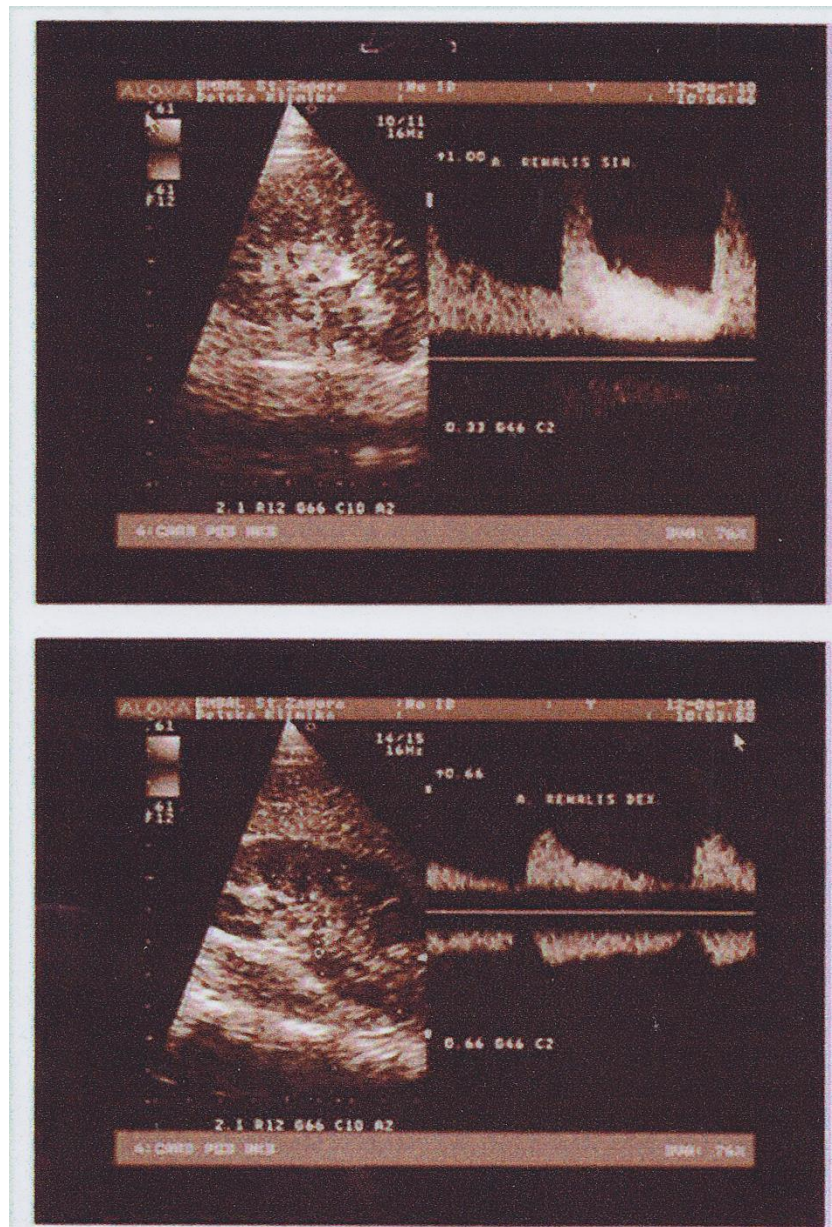


Figure 3a, b. Kidney ultrasound: enlarged kidneys with increased echogenicity of parenchyma and edematous parenchyma. Doppler sonography of renal artery –normal blood flow in the two renal arteries

Further laboratory tests including platelet count, hemostatic tests, bilirubin blood test, total serum protein and albumin, LDH, ANA, anti-ds DNA, ANCA, Ig A, Ig M, cryoglobulins, anti Rickettsia conorii Ig M, Ig G, hemocultures, urocultures, hepatic markers, Coombs tests, ECG, Echocardiography were normal or negative.

The comprehensive differential diagnostic plan ruled out Sepsis, Systemic vasculitis, Cryoglobulinemia vasculitis, Hypocomplementemic urticarial vasculitis, Henoch-Schönlein purpura, Scarlet fever, Mononucleosis infection, Rickettsial diseases, Malignant hemopathy and etc. (11-13). In terms of differential diagnosis, we have excluded hypocomplementary urticaria vasculitis, due to the absence of an urticarial rash and the loss of the characteristic systemic manifestations such as angioedema, arthralgias, abdominal pain, pulmonary involvement and ANA negative result (14). Granulomatosis with Polyangiitis (GPA, formerly Wegener Granulomatosis) is excluded due to lack of clinical data on skin ulcerations, without involvement of lower respiratory tract and arthritis, with reverse resolution of acute nephritic syndrome and negative Antineutrophil cytoplasmic antibody testing. The absence of a characteristic hemorrhagic rash, no joint and abdominal pain syndrome, and normal IgA values, make the diagnosis of Henoch-Schönlein purpura unlikely.

As a result of the conducted treatment with: Sumamed, Furantril, Nifedipin, Isoprinosin, Ca gluconici, Xyzal, Antistenocardin the pathological syndromes withdrew after two weeks. On discharge from the hospital the only pathologic finding was the microhaematuria. Normalization of complete blood count and renal function parameters was observed at dehospitalization. During the follow – up visits in the next thirty-six months clinical and laboratory abnormalities were not registered.

DISCUSSION

We present a case of a 13-year-old girl with an evolving clinical picture of hypersensitivity vasculitis in the course of severe β hemolytic streptococcus and EBV co-infection and prior antibiotic treatment, of complete clinical recovery. Of significance, are the findings of febrile-intoxication syndrome with septic fever, generalized lymphadenomegaly, hepatosplenomegaly, cutaneous eruptive syndrome with maculopapular eruption at the

onset and with hemorrhagic character dynamically on face, neck, legs and upper limbs, bilateral conjunctival ecchymosis (fig.2), eyelid haematomas, epistaxis and tonsillitis with tonsillar haemorrhage.

Hypersensitivity vasculitis (HV) is often used to describe different types of vasculitis related to specific drugs or infection but it may also be idiopathic. Associations of hypersensitivity vasculitis with β hemolytic streptococcus, HCV, HIV infection have been described in the literature (4). Rheumatoid arthritis, Sjögren syndrome, lupus erythematosus, Inflammatory bowel disease, ulcerative colitis, or Crohn colitis and Lymphoproliferative diseases may be associated with cutaneous vasculitis (6,10).

The presence of a skin rash, usually red spots, is the main symptom of HV (2). A biopsy of these skin spots reveals inflammation of the small blood vessels, called leukocytoclastic vasculitis. Although the exact mechanisms of hypersensitivity vasculitis are not fully understood, hypersensitivity vasculitis is thought to be mediated by immune complex deposition (5) In this form of vasculitis, circulating antigens in the body (produced by factors such as medications, infections, and neoplasms) induce antibody formation. These antibodies bind to the circulating antigen and create immune complexes, which then deposit within vessels, activating complement and inducing inflammatory mediators (7, 8).

The major symptoms of HV, in addition to a skin rash, are joint pains and increasing size of lymph nodes (9). In the case we described, the child had no joint complaints and no visible changes in large and small joints. Organ involvement in addition to the skin rash is very rare, but can be severe. (11) Kidney inflammation and even more rarely liver, lung, heart and brain injury have occurred in patients with HV. Kidney failure is not common. Kidney failure can be „acute“, meaning there is a fast loss of kidney function. Four types of renal involvement associated with drug allergy and infection: interstitial nephritis; PAN-like microscopic nephroangiitis; focal necrotizing glomerulonephritis; diffuse proliferative glomerulonephritis. (12)

In our case an acute nephritic syndrome presents with macroscopic hematuria moderate proteinuria, oliguria, acute renal failure, hypertension, volume overload, hypocomplementemia. He is associated with

inflammation and proliferation of the glomerular tuft and is immunologically mediated. Complete clinical recovery and laboratory improvement of hematological and immunological parameters gave us the reason not to perform a diagnostic renal puncture.

The history for several tick bites, contact with dogs and positive enzyme-linked immunoassay (ELISA) for *Borrelia burgdorferi* detected in the active phase of the disease, required additional diagnostic procedures to clarify its role in the whole clinical presentation. During the three follow up visits in the next 12 months serological tests for *B. burgdorferi* were negative both for IgM and IgG. The lack of the characteristic rash - erythema migrans in the acute phase and the negative serological results in the follow up period comprise strong evidence against infection with *B. burgdorferi*. The first positive serology for *B. burgdorferi* is due to cross reaction with the EBV. The association of false-positive results of serological testing for Lyme disease with infection due to a herpesviruses is reported in literature (15).

CONCLUSIONS

This case is a demonstration of a severe clinical course of hypersensitivity vasculitis with acute nephritic syndrome as a result of the identified mixed infection with beta-hemolytic streptococcus and EBV infection. The clinical course is due to the development of complicated pathogenic and immunologic mechanisms. The positive serology for *B. Burgdorferi* without the presentation of the specific symptoms of Lyme disease is due to cross reaction. Long-term clinical and laboratory follow-up showed complete recovery.

REFERENCES

1. Arora A, Wetter DA, Gonzalez-Santiago TM, Davis MD, Lohse CM. Incidence of leukocytoclastic vasculitis, 1996 to 2010: a population-based study in Olmsted County, Minnesota. *Mayo Clin Proc.* 2014 Nov. 89 (11):1515-24.
2. Gonzalez-Gay MA, Garcia-Porrúa C, Pujol RM. Clinical approach to cutaneous vasculitis. *Curr Opin Rheumatol.* 2005 Jan. 17(1):56-61.
3. Gonzalez-Gay MA, Garcia-Porrúa C, Pujol RM. Clinical approach to cutaneous vasculitis. *Curr Opin Rheumatol.* Jan 2005;17(1):56-61.

4. Chen KR, Carlson JA. Clinical approach to cutaneous vasculitis. *Am J Clin Dermatol.* 2008. 9(2):71-92.
5. Kevil CG, Bullard DC. Roles of leukocyte/endothelial cell adhesion molecules in the pathogenesis of vasculitis. *Am J Med.* Jun 1999;106(6):677-87.
6. Blanco R, Martinez-Taboada VM, Rodriguez-Valverde V, Garcia-Fuentes M. Cutaneous vasculitis in children and adults. Associated diseases and etiologic factors in 303 patients. *Medicine (Baltimore).* Nov 1998;77(6):403-18.
7. Kevil CG, Bullard DC. Roles of leukocyte/endothelial cell adhesion molecules in the pathogenesis of vasculitis. *Am J Med.* Jun 1999;106(6):677-87.
8. Sams WM Jr. Hypersensitivity angiitis. *J Invest Dermatol.* Aug 1989;93(2 Suppl): 78S-81S.
9. Garcia-Porrúa C, Gonzalez-Gay MA. Comparative clinical and epidemiological study of hypersensitivity vasculitis versus Henoch-Schönlein purpura in adults. *Semin Arthritis Rheum.* Jun 1999; 28(6):404-12.
10. Xu LY, Esparza EM, Anadkat MJ, Crone KG, Brasington RD. Cutaneous Manifestations of Vasculitis: A Visual Guide. *Semin Arthritis Rheum.* Mar 18 2008;
11. Zurada JM, Ward KM, Grossman ME. Henoch-Schonlein purpura associated with malignancy in adults. *J Am Acad Dermatol.* Nov 2006; 55(5 Suppl): S65-70.
12. Carlson JA, Ng BT, Chen KR. Cutaneous vasculitis update: diagnostic criteria, classification, epidemiology, etiology, pathogenesis, evaluation and prognosis. *Am J Dermatopathol.* Dec 2005; 27 (6):504-28.
13. Carlson JA, Cavaliere LF, Grant-Kels JM. Cutaneous vasculitis: diagnosis and management. *Clin Dermatol.* Sep-Oct 2006; 24(5):414-29.
14. Wisnieski JJ, Baer AN, Christensen J, et al. Hypocomplementemic urticarial vasculitis syndrome. Clinical and serologic findings in 18 patients. *Medicine (Baltimore).* Jan 1995; 74 (1):24-41.
15. Lynne Strasfeld et al False-Positive Serological Test Results for Lyme Disease in a Patient with Acute Herpes Simplex Virus Type 2 Infection *Clinical Infectious Diseases*, Volume 41, Issue 12, 15 December 2005, Pages 1826–1827

