



Original Contribution

A TECHNICAL NOTE ON SAFE DEFINITIVE EXTERNALIZED LOCKED PLATING FOR BIOLOGICAL FRACTURE HEALING IN COMPLEX TIBIAL FRACTURES

B. Makelov*

University Multiprofile Hospital for Active Treatment, Trakia University, Stara Zagora, Bulgaria

ABSTRACT

Purpose. This technical note describes a minimally invasive surgical technique for early appropriate care in patients with high-energy, multifragmentary tibial fractures by means of safe one-stage external stabilization with angle-stabled plates. The purpose of the presented prospective case series study was, to explore the clinical feasibility and research the biomechanical parameters and of externalized locked plating and, to test the functional result and clinical outcomes following the novel technique for definitive surgical treatment for complex - meta-diaphyseal multifragmentary, proximal (with simple intra-articular) and distal (multifragmentary metaphyseal), fractures of the shin bone.

Methods: Thirty-three patients participated in the prospective feasibility study, carried out from August 2012 to September 2023. The precise inclusion criteria were: sustained high-energy tibial trauma and severe soft tissue injury, with complex proximal and distal meta-diaphyseal tibial fractures, stabilized with externalized locked plating. **Results:** Eighteen of the patients from the prospective cohort included in the study were followed up for an average of 21.4 ± 12.3 months, union rate of 94,7%. All fractures healed by means of secondary bone union and with minor complications. We reached a significantly shorter mean union time was 21.1 ± 4.6 weeks, for patients with proximal extra- versus intra-articular meta-diaphyseal tibial fractures, $p = 0.04$. According to HSS and AOFAS scores, good and excellent functional results in knee and ankle joints' range of motion were accomplished among 90 percents of the patients. However, there were no registered implant de-bricolage, non-union or severe deep infection. We had two patients with re-fracture between the fourth and sixth week after external plate removal, who underwent secondary surgical procedure for successful bone healing. Several screws were loosened in nine patients from the cohort, with no negative effect on the bone union process.

Conclusions. The currently reported technique for one-stage supercutaneous fracture stabilization by means of externalized locked plating is a novel surgical procedure for a safe external fracture fixation with LISS-DF plate. The definitive externalized fracture plating is a viable surgical solution for natural bone union in complex – multifragmentary meta-diaphyseal tibial fractures with injured soft tissue envelope.

Key words: Tibia, open fractures, soft tissue injury, externalized supercutaneous plating.

INTRODUCTION

Multifragmentary metadiaphyseal tibial fractures represent a heterogeneous group of injuries, often caused by high-energy trauma, with a prevalence between 2% and 11%. These injuries usually result in disability with high socioeconomic costs [1-6].

Due to their great variety combined with injured soft tissue coverage, it is difficult to apply standard surgical procedures, which represents

a real challenge for modern orthopaedic surgeons [6–9].

Contemporary operative techniques and methods for definitive fixation include the use of locking plates, intramedullary nails, and/or external fixation devices [10–16]. In polytrauma cases with unstable (complex) meta-diaphyseal tibial fractures, especially those with severe local soft tissue injury the precise timing of early appropriate surgical treatment is a matter of greater importance. Nevertheless, there are some issues that need to be addressed for a

*Correspondence to: Biser Makelov, University Multiprofile Hospital for Active Treatment, Trakia University, 6003 Stara Zagora, Bulgaria
dr_makelov@hotmail.com

successful treatment of multifragmentary meta-diaphyseal tibial fractures, and that can be summarized as follows: The correct timing of intervention, the choice between staged or single-stage approach, and selection of appropriate surgical instrumentation to minimize additional surgical trauma to the primary injured soft tissues at the fracture site. The duration and complexity of the surgical intervention are critical for achieving an optimal end result. The application of a locking plate as an external fixator for definitive surgical treatment of open tibial fractures is not a new operative technique [17–19]. Recently, an excellent final clinical result has been reported, highlighting the advantage of the operative technique, in terms of less additional tissue injury and sufficient axial and torsional stability when compared with conventional methods of fracture stabilization [19–32]. Several studies have focused on experimental, computational finite element modelling systems to investigate the biomechanical characteristics of the externalized locked plating, such as stability and durability of the construct. The stiffness parameters of the plate-bone interface with different distance of the bone in comparison with standard monolateral external fixation devices summarise, that the durability and flexibility of the former, significantly depends on the amount of plate elevation. Our previous work has shown that the use of external locked plating for definitive fracture fixation results in uneventful secondary fracture healing, when applied to carefully selected cases. Therefore, supracutaneous external fracture stabilization with the LCP (LISS DF) plate requires a low-profile design with locking plate placement as close as possible to the skin. However, with appropriate distance of

the plate from the bone, the interfragmentary deformity in the fracture region under early partial weight-bearing (PWB) was within the range indicated for secondary bone union [21, 33–37, 44]. The aims of the study were, first, to investigate the clinical feasibility of Definitive External Locked Plating (DELP) based on precise computational biomechanical parameters and, second, to evaluate the clinical and functional outcomes following the application of DELP for the treatment of multifragmentary, proximal (intra- and extra-articular) and distal (extra-articular) high-energy meta diaphyseal tibial fractures.

MATERIALS AND METHODS

After a detailed explanation of the surgical procedure, signed informed consent was obtained from all participants. Institutional review board approval prior to initiation of the prospective feasibility study was obtained on 11/27 June 2019.

1. Patients enrolled in the study.

Patients with high-energy Multifragmentary meta diaphyseal tibial fractures were included in the prospective study and were treated with Definitive Externalized Locked Plating from 2013 to 2023. The precise inclusion criteria were patients over 18 years of age, and those with radiologically confirmed diagnosis of multifragmentary extraarticular fractures of the proximal tibia, simple intraarticular fractures of the proximal tibia without comminution and fragmentation, multifragmentary extraarticular meta diaphyseal fractures of the distal tibia with significant soft tissue injury or open tibial fractures with suspected severe wound contamination (**Table 1**) and (**Figure 1A, B, C, D**).

Table 1. Fractures and soft tissue classification according to AO/OTA system.

Classification	Type/Grade	Number of Patients	Gender
AO/OTA fracture classification	41-C2.2	7	M
	41-C2.3	1	F
	41-A3.1	2	M
	41-A3.1	2	F
	42-C3j	2	M
	43-A2.1	1	M
	43-A2.3	3	M
AO soft tissue grading system	IO2	7	M
	IO2	3	F
	IO3	6	M
	IO4	2	M

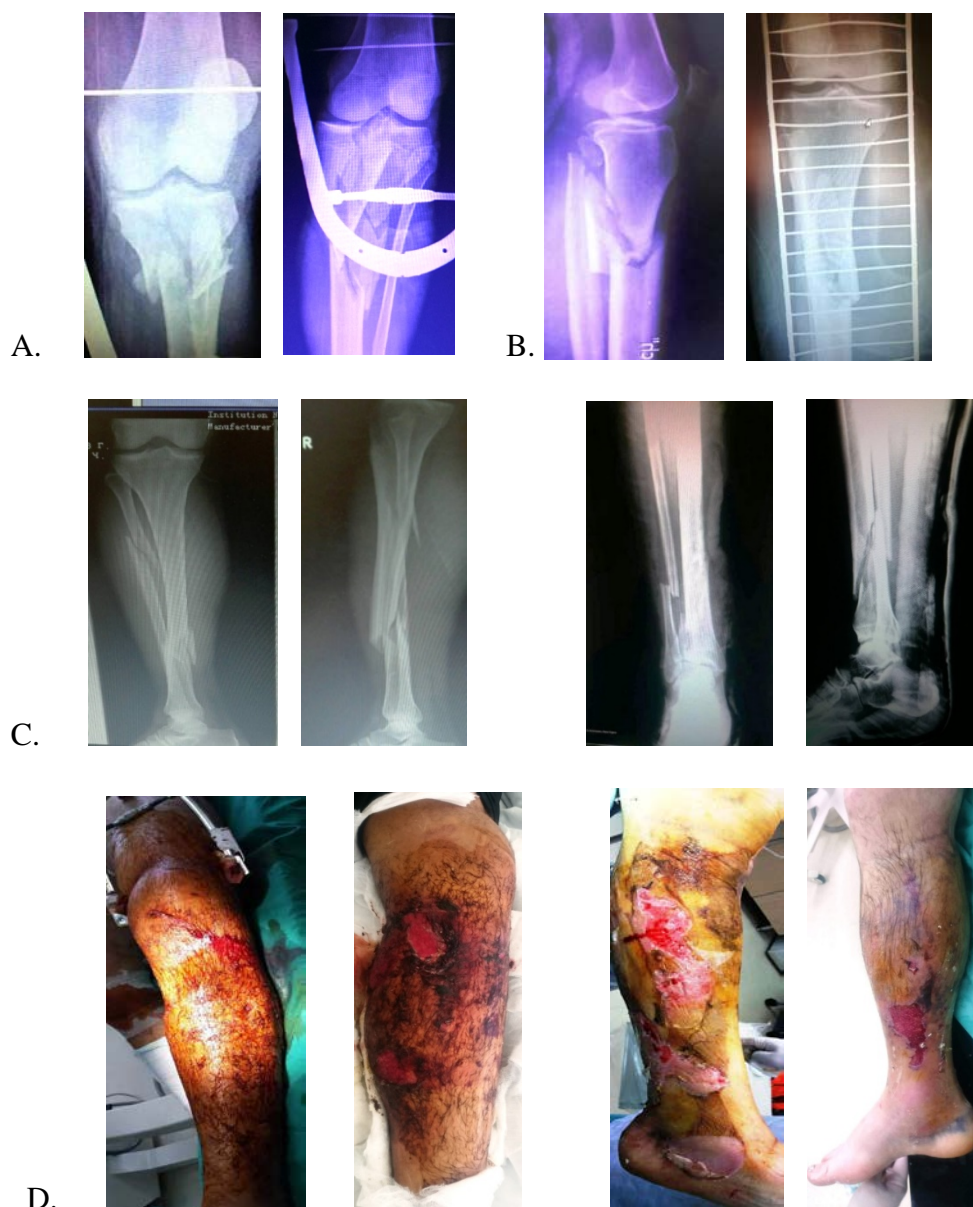


Figure 1. A. AO/OTA 41C2.2 - simple intra-articular involvement of without comminution and impaction. **B.** AO/OTA 41 A3.1 multi-fragmentary proximal extra-articular fracture of the tibia. **C.** AO/OTA 43 A2.3 distal meta-diaphyseal fracture. **D.** Complex fractures with severe soft tissue injury - clinical pictures.

2. Surgical Technique

Patient setup

Patients were placed in the supine position, with the knee semi-extended at about 30-45°, assisted by a rolled gauze under the knee to counteract the action of muscle forces and thus reduce tip and anterior deformities. The biomechanical axis of the lower limb was restored and confirmed intraoperatively in coronal plane by the Bowie technique using a cautery cord. In addition, before final fixation of the fracture, the absence of malalignment in axial plane without any apex-anterior or apex-posterior deformities in the sagittal plane was checked and confirmed. For intraoperative evaluation of rotational malalignment, the

Clemens alignment method, modified from Eckhardt's technique was preferred [38].

Articular Joint Surface Reduction.

In patients with simple intra-articular fracture of the proximal tibia, anatomic reduction of the articular surface was achieved at the beginning by means of ligamentotaxis and indirect reduction approach with compressive percutaneous fixation techniques, using one or two 6.5-mm cannulated screws or three 3.5-mm subchondral rafting screws, thus converting the fracture pattern from AO/OTA 41C2. 2 to 41A3. The joint capsule of the knee joint was preserved intact, thus avoiding the risk of deep infection or septic arthritis with subsequent knee stiffness, and permanent disabling contracture.

Definitive Externalized Locked Plating.

Eleven-hole LISS DF plates were used as an external monolateral bridging splint, with the area of the holes (holes A to G, **Figure 2**) offering an opportunity for adequate purchasing of the locking screws in the short metaphyseal tibial segment. Ipsilateral, inverted plates (left LISS DF for left proximal tibia) were applied to stabilize proximal, metadiaphyseal fractures, whereas contralateral, noninverted plates were used to treat distal, metadiaphyseal fractures. Nine locking screws (No.1 to No.9) of an appropriate length and specific placement sequence were used as shown, and (**Figure 2 A, B, C**) at least a 15 mm safety distance, to the articular surface was ensured to avoid knee joint

penetration. For that purpose, a temporary subchondral Kirschner (K-) guide wire was introduced from the medial to lateral direction under the C-arm. Then, with another K- wire, inserted into the E-hole, the plate was positioned parallel to the anteromedial aspect of the tibia. Only, if necessary, additional small stab incisions were made to aid reduction. Manipulation of the fragments through the primary wound in open fractures was possible after debridement and copious irrigation of primary wound to reduce the risk of subsequent infection. Manual traction (ligamentotaxis) was applied along to the long axis of the limb to for adequate fracture alignment.




Figure 2. A, B. LISS DF plate -proximal segment screw distribution. **C.** Externalized locked plating with sample sequence of screw insertion into the locking LISS plate.

Initially, screw No.1 was placed in one of the holes of the cluster zone (A to G, **Figure 2 C**), parallel to the articular surface and was tightened, but not locked yet. Under C-arm control, the screw purchase direction, was chosen to avoid penetration into the fracture lines. The screw length was calculated by adding the predetermined plate elevation from bone (15 to 30 mm) to the measured screw depth, considering the presented thinner or thicker skin coverage and the presence or absence of soft tissue oedema. Then screw No.2 of the appropriate length was inserted into hole number eight of the plate, which was tightened but not locked either. Thus, a splinting construct was built with a predetermined plate-bone offset

(height), with adequate alignment of the fractured bone, and a defined initial plate working length. A tighten, but not locked, screw No.3 (drop screw) was then placed straight beneath the diaphyseal edge of the fracture zone to minimize shear forces and to determine the effective final external plate working length, that corresponded to the fracture boundaries. At that stage, a mandatory fluoroscopic check was performed to verify the alignment in the frontal and sagittal planes. Three more screws were inserted and locked, and all remaining screws (No.4 to No.9), were inserted and locked either (**Figure 3**).

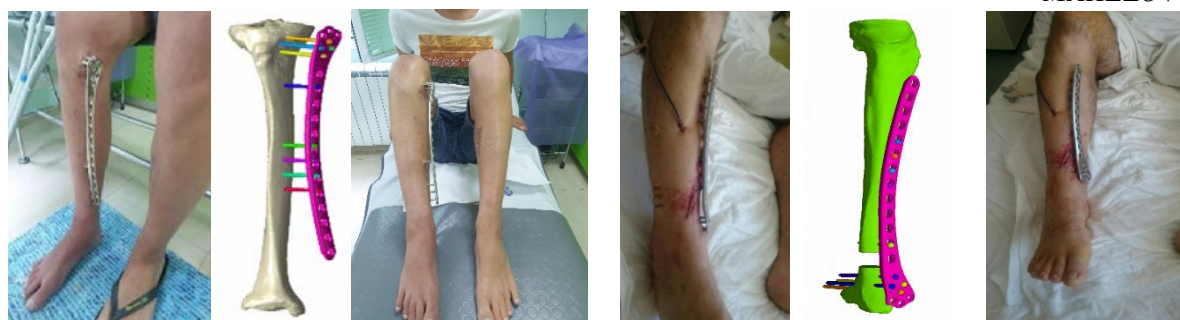

Figure 3. Personal photographs of patients with proximal (left) and distal (right) meta diaphyseal fracture fixed by externalized locked plate using ipsilateral inverted or contralateral noninverted LISS-DF plate, respectively.

Computational biomechanical analysis of the bone-plate-fracture interface.

To investigate the biomechanical stability of externalized locked fixation of proximal and distal unstable tibial fractures, bone-implant

constructs with variable elevation from bone representing different soft tissue envelope thicknesses, were evaluated, and compared using finite element (FE) simulations adopted from previous work [44].

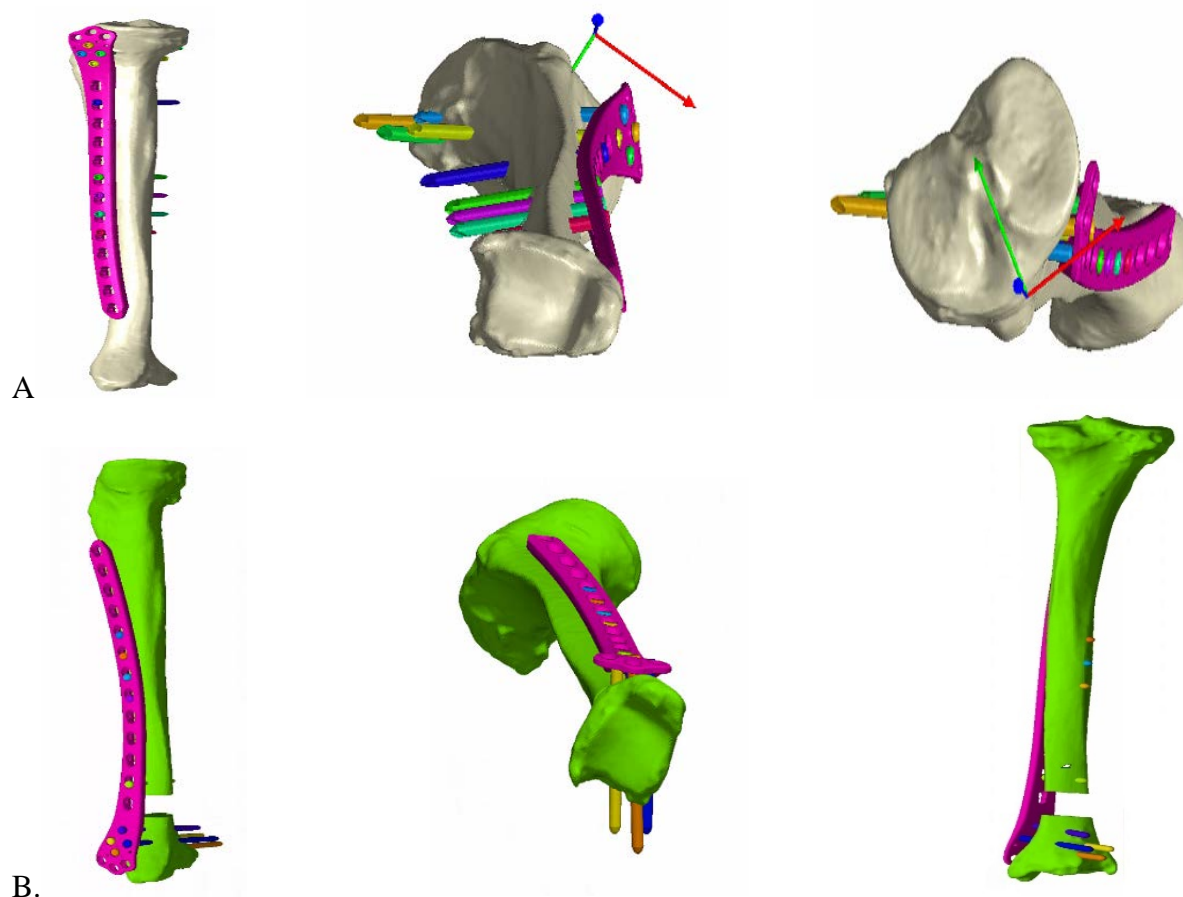


Figure 4. A. Antero-medial coronal and lateral views of virtual 3D model of bone-plate construct with an unstable proximal tibial fracture. **B.** Unstable distal tibial fracture (mimicking a compound fracture by osteotomizing a 20-mm gap and fixed with a 22-mm plate elevation, representing an externalized locked cover with a soft tissue thickness of 20 mm).

The FE models were meshed with square hexahedral elements, using Simple ware software (Simple ware Ltd., Exeter, UK), and the elastic properties of the bone elements were

correlated based on BMD baseline values using an established relationship (**Figure 4 A, B**) [41]. The elastic properties of stainless steel were determined for the screws and plate (Young's modulus: 210 GPa; Poisson's ratio: 0.3). The

screw-bone and screw-plate interfaces were determined to be bonded. The boundary conditions reproduced an axial load of 250 N or 800 N, representing partial or full weight bearing, respectively, as described previously [38]. Finite element analyses were performed using Abaqus (V.2019, Simulia, Dassault Systemes, Velizy-Villacoublay, France). Fracture gap motion was measured by tracking the displacement of two nodes on the fracture plane in the far cortex. The fracture deformation (*strain*) was calculated by dividing the amount of interfracture motion by the fracture width of 20 mm.

Postoperative protocol for early controlled PWB.

From the first to the seventh day after surgery, patients began to walk on the toes of the affected foot. At the third postoperative week, in the later phases of callus maturation with clinical evidence of fracture stability, walking was performed with the PWB on the limb until radiographic confirmation of callus formation.

After successful radiographic confirmation of callus formation by the twelfth postoperative week, full weight bearing (FWB) of the affected limb was initiated. In the absence of patient complaints, four weeks after FWB without aided support and after a new set of orthogonal radiographs, the external plate was removed without anaesthesia in the outpatient setting.

Statistical analysis and data collection.

All patients in the present study were followed up with orthogonal radiographs at 24 hours postoperatively, at the third, sixth, and twelfth weeks, and at two-month intervals thereafter. Patients were analysed in different subgroups based on the following categories: age less than 50 years and more than 50 years, location of fracture (proximal or distal tibial meta diaphysis), severity of fracture based on the presence or absence of joint involvement (simple or complex), and degree of soft tissue damage (based on the AO soft tissue scoring system: mild or severe). Four categories were used to assess clinical outcomes: operative time, fracture healing time, functional assessment scores using the Hospital for Special Surgery (HSS) (to assess the knee joint) and the American Orthopedic Foot and Ankle Score (AOFAS) (to assess the ankle joint), and knee and ankle joint range of motion (ROM) at the fourth week after surgery and at the final follow-up one month after plate removal. At

each consultation, the leg was checked for signs of superficial infection and/or screw loosening. Statistical analysis was performed with the SPSS software package (V.27, IBM, Armonk, NY, USA). The normality of the data distribution was checked and proved by the Shapiro-Wilk test. Mann-Whitney and Wilcoxon Signed - Rank tests were performed to detect significant differences between different subgroups of patients according to the defined categories and the significance level was set at 0.05 for all statistical tests.

RESULTS

1. Clinical Outcomes

Thirty-three patients participated in the feasibility project. The prospective cohort study included 18 patients (15 men and 3 women) aged 53.8 \pm 15.9 years (mean \pm standard deviation, range 22-85 years). Most patients in the cohort (83%) underwent surgery after stabilization of their vital signs and within the first 24 hours of admission. Skeletal traction for more than 24 hours was used in 3 (17%) patients who had multiple injuries to provide temporary fracture stability. All patients were followed for a period of 21.4 \pm 12.3 months (range 14-60 months). The duration of surgery was 33.9 \pm 7.1 min (range 20-45 min), and intraoperative X-ray irradiation lasted 19.6 \pm 7.9 s (range 11-43 s). In 17 cases (94%), the fractures healed without complications; the mean healing time was 21.1 \pm 4.6 weeks (range 12-29 weeks). Patients with simple, extra-articular, multifragmentary fractures had significantly shorter healing times compared with patients with complex intra-articular fractures ($p = 0.04$). No other significant differences in clinical outcomes were found between patient subgroups.

2. Complications

There were two patients with delayed union followed by refracture 6 weeks after the plate removal, one patient with a varus knee joint of seven degrees with a leg length difference of 2.5 cm, one case with extensor knee contracture due to septic arthritis, and nine cases with screw-loosening of sixteen of all screws applied for externalized locked plating in the researched cohort. No screw or plate breakage or deep infections, were observed (**Figure 5**). In 4 patients, there was mild, superficial skin irritation around the screw entry orifices of grade 1-2 according to the Checketts-Otterburn classification with skin granulation up to 4 mm: Three patients had skin granulation of 4 to 10

mm, and one patient had bleeding skin vegetations (hyper granulation with secretion) (**Figure 6**). In one patient, plastic repair of the primary wound was necessary. In another patient with severe soft tissue injury and an open fracture, fasciotomy was performed, although there were no clinical signs of

compartment syndrome. On the first day after surgery, a significant reduction of posttraumatic soft tissue oedema of the injured leg was observed, and by the end of the first postoperative week it had completely disappeared, probably due to early active rehabilitation.

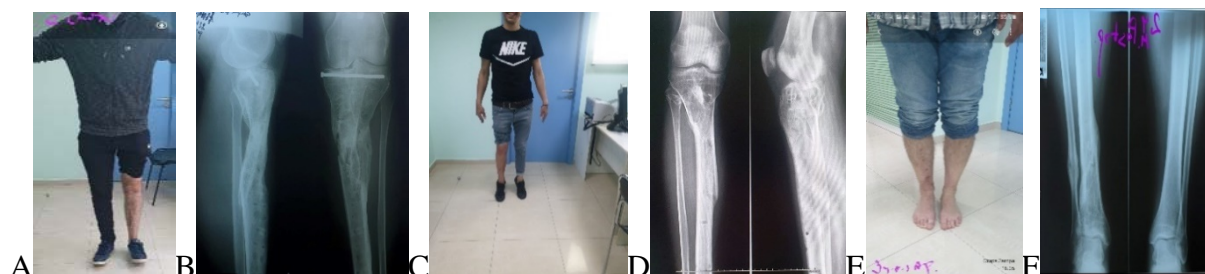

Figure 5. Final follow-up (A, B, C) and (D, E, F) of patients with fracture type AO/OTA 41C2.2 - healed proximal tibial fracture with simple intra-articular involvement of both tibial condyles without intra-articular comminution and impaction (radiographs A, B), an AO/OTA 41-A3.1 healed multifragmentary proximal tibial extra-articular fracture (radiographs C, D), and healed AO/OTA 43-A2.3 distal tibial multi-fragmentary meta-diaphyseal fracture (radiographs E, F), all were accompanied by significant soft tissue injuries and treated via Definitive Externalized Locked Plating.

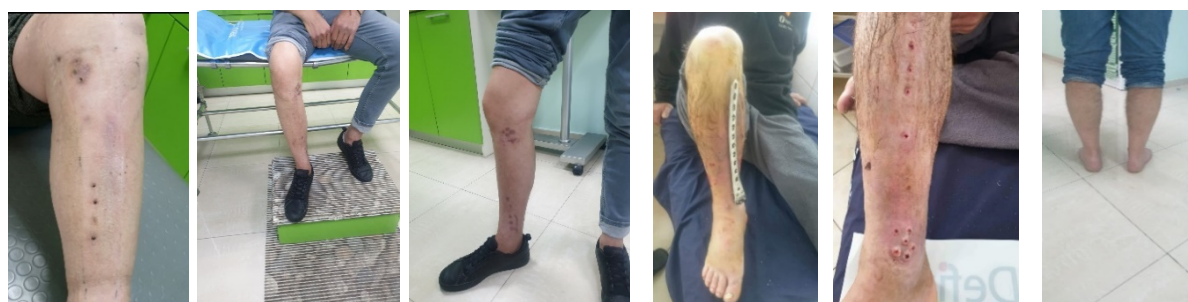

Figure 6. Clinical appearance – after plate removal and at the final follow-up.

3. Functional Outcomes

In each separate subgroup, all functional outcomes, except knee joint ROM in extension, demonstrated a significant increase between the fourth week after surgery and the final follow-up ($p < 0.04$). HSS was significantly lower for patients with complex versus simple fractures in the fourth week after surgery ($p = 0.04$). Knee joint ROM in flexion was significantly higher at the fourth week after surgery for patients suffering distal versus proximal fractures and at the final follow-up for patients younger versus older than 50 years ($p < 0.01$). The ankle joint ROM in plantar flexion was significantly higher in the fourth week after surgery for younger patients versus older than 50 years ($p = 0.04$). No other significant differences in functional outcomes were found among relevant patient subgroups.

DISCUSSION

Our prospective cohort study was focused on the clinical and functional outcomes associated

with definitive external locking splinting of multifragmentary, proximal intra-articular, and distal extra-articular meta diaphyseal tibial fractures. The promising clinical results in this study were supported by the computational results of the virtual biomechanical analysis performed, which concluded that interfragmentary motion during the early postoperative period remained within the range indicated for uneventful secondary fracture healing. Adapted for the treatment of fractures with special indications, the technique of external, low-profile, locking plate fixation provided a viable and attractive alternative to conventional methods of external fixation and may have had a higher rate of patient acceptance while not compromising fixation stability [18, 25, 37, 44].

The presented technique was characterized by relative simplicity of performance, less soft tissue scarring with less additional soft tissue injury, improved cosmetic appearance, and

more convenient implant removal, thus meeting the criteria for biologic fixation and therefore reducing the risk of complications. [20, 23–25, 41].

Its use, especially in the setting of a single-staged surgical intervention, can shorten the overall duration of surgery, diminish the time for intraoperative X-ray exposure, and reduce both the length of hospitalization and medical costs. The externalized locking plate acts as a supportive monolateral, external splinting device. Thus, it provides relative stability, needed for the secondary healing of the fracture by easily maintaining skin hygiene around the screws, being less noticeable and aesthetically acceptable to the patient [6]. Due to its low profile, the plate can be placed very close to the skin and then easily hidden under the patient's clothing, thus overcoming the disadvantages of a conventional external fixator [32, 42]. Typically, both techniques, which use either conventional external fixators or externalized locking plates, rely on fixed-angle stabilization, either between the pins and the fixator sidebar or between the screws and the plate, to span the fracture at a fixed distance along the bone surface without any significant additional irritation to the periosteal blood supply [37, 43]. Furthermore, to achieve a suitable mechanical environment for secondary bone healing, both techniques allow minimally invasive osteosynthesis and an opportunity to modulate the stiffness of the construct to a certain degree [37, 45]. However, despite the presumed similarities between the techniques, there are some significant differences, which relate primarily to the methods of control of the strain at the fracture site, the degree, and the extent to which the construct stiffness can be modulated [37]. While conventional external fixators can be applied in a variety of frame configurations, allowing more appropriate stiffness control over a wide range of pin configurations, the range over which the stiffness of an external locking plate construct can be modulated is much narrower, if compared to standard external techniques, because the number of screw holes that can be occupied is limited [37,46]. Furthermore, unlike conventional external fixators, it is not possible to increase the number of rods/respectively screws to increase the stiffness of the construct when a definitive externalized locked plating technique is applied [37]. Another significant difference between the two techniques is that the externalized locked plating requires a good reduction prior to final

screw locking fixation, due to the limited possibilities for additional adjustments of the bone fragments, that can be made afterward.

The externalized locked fixation has the following disadvantage: it can be difficult to position the plate and adjust the direction of each individual screw, both because of the locking mechanism and because of the precise intra articular fracture site reduction, that must be achieved and maintained [20]. Variable-angle locking technologies offer more freedom in regard, allow to some extent even an individual screw orientation.

However, the surgical technique associated with single-stage externalized locked fixation was adapted in the present study to: (1) achieve appropriate indirect fracture reduction, (2) temporarily optimal positioning and alignment of the plate in the coronal and sagittal planes, along with the predetermined plate elevation and the specified initial fixation range, (3) initial sequential insertion and tightening of all screws in the plate holes without locking, (4) fluoroscopic inspection to verify alignment in the coronal and sagittal planes, and (5) locking of the inserted screws in a predetermined sequence. The operative time in the present study, was similar for unstable proximal and distal meta diaphyseal simple and complex fractures were comparable to previous reports [23, 24]. The fracture healing time in the present work, was significantly different for patients with intra-articular and extra-articular fractures. It was within the reported healing time range in previous studies [6, 21, 24]. The presented HSS and AOFAS scores assessed in the fourth week after surgery and at the last follow-up were consistent with previous studies [21]. In all patients in the current cohort, plate to bone elevation was equal to or less than 30 mm to maintain a stable fracture fixation in accordance with previous studies [33, 47]. In a prospective series of 25 patients with segmental tibial fractures treated by a two-stage procedure including supercutaneous locked splinting, the reported rates of excellent and good functional outcomes were 84% and 16%, respectively [22]. In a review of a clinical study on a total of 254 patients treated with externalized locked plating, only 2 cases of nonunion were reported with an average bone union rate of 99.2% (range 95.7 - 100%), and a low rate of implant complications, with only 1 broken plate, 5 cases with 6 loose screws, and 3 cases with 4 broken screws [6].

In the present study, the rate of bone union was 94.7%, with no screw or plate breakage and 9 cases with 16 loosened screws. The results of the virtual biomechanical analysis confirmed previous findings, that partial weight bearing is possible in fractured meta-diaphyseal tibia fixed by external locked plating with plate elevation up to 30 mm when patients' activities are carefully considered and strictly controlled in the early postoperative phase [33, 35, 44]. Limitations of the present study include the degree of generalization of the results, given the small cohort size of patients treated at a single medical center by a single surgeon, the risk of errors, and the lack of a control group. In fact, an important strength of the study was the inclusion of patients with both proximal (intra-articular and extra-articular) and distal (extra-articular) metadiaphyseal tibial fractures. Another important advantage is the high patient acceptance of the definitive externalized locked plating technique. In addition, all surgical procedures and follow-up patient's evaluations were performed by a single surgeon at a single centre with the same technique contributes to the validity of the result. More randomized, multicentric, prospective clinical trials are needed to confirm the above-mentioned good clinical results and excellent functional outcomes.

CONCLUSIONS

Definitive externalized locked plating applied to carefully selected patients, who meet the strict inclusion criteria, provides adequate biologic fixation, and yields promising clinical outcomes. Externalized locked fracture fixation represents an attractive minimally invasive, one-staged biologically safe surgical technique, when compared to conventional methods of external fixation. The success of the presented technique is assured when surgeons precisely follow to the inclusion criteria, surgical algorithm, sequence of screw purchasing and the early postoperative rehabilitation protocol.

REFERENCES

1. Catagni, M.A.; Ottaviani, G.; Maggioni, M. Treatment strategies for complex fractures of the tibial plateau with external circular fixation and limited internal fixation. *J. Trauma* 2007, 63, 1043–1053. [CrossRef] [PubMed]
2. Gosling, T.; Schandelmaier, P.; Muller, M.; Hankemeier, S.; Wagner, M.; Krettek, C. Single lateral locked screw plating of bicondylar tibial plateau fractures. *Clin.*

- Orthop. Relat. Res.* 2005, 439, 207–214. [CrossRef] [PubMed]
3. Bove, F.; Sala, F.; Capitani, P.; Thabet, A.M.; Scita, V.; Spagnolo, R. Treatment of fractures of the tibial plateau (Schatzker VI) with external fixators versus plate osteosynthesis. *Injury* 2018, 49 (Suppl. 3), S12–S18. [CrossRef] [PubMed]
4. Yang, S.W.; Tzeng, H.M.; Chou, Y.J.; Teng, H.P.; Liu, H.H.; Wong, C.Y. Treatment of distal tibial metaphyseal fractures: Plating versus shortened intramedullary nailing. *Injury* 2006, 37, 531–535. [CrossRef] [PubMed]
5. Zelle, B.A.; Bhandari, M.; Espiritu, M.; Koval, K.J.; Zlowodzki, M. Treatment of distal tibia fractures without articular involvement: A systematic review of 1125 fractures. *J. Orthop. Trauma* 2006, 20, 76–79. [CrossRef]
6. Luo, P.; Xu, D.; Wu, J.; Chen, Y.H. Locked plating as an external fixator in treating tibial fractures: A PRISMA-compliant systematic review. *Medicine (Baltimore)* 2017, 96, e9083. [CrossRef]
7. Lau, T.W.; Leung, F.; Chan, C.F.; Chow, S.P. Wound complication of minimally invasive plate osteosynthesis in distal tibia fractures. *Int. Orthop.* 2008, 32, 697–703. [CrossRef]
8. Scolaro, J.A.; Broghammer, F.H.; Donegan, D.J. Intramedullary Tibial Nail Fixation of Simple Intraarticular Distal Tibia Fractures. *J. Orthop. Trauma* 2016, 30 (Suppl. 4), S12–S16. [CrossRef]
9. Kalinterakis, G.; Koutras, A.; Syllaios, A.; Michalakeas, N.; Lytras, D.; Tsilikis, I. The evolution and impact of the “damage control orthopedics” paradigm in combat surgery: A review. *Eur. J. Orthop. Surg. Traumatol.* 2019, 29, 501–508. [CrossRef]
10. Hasenboehler, E.; Rikli, D.; Babst, R. Locking compression plate with minimally invasive plate osteosynthesis in diaphyseal and distal tibial fracture: A retrospective study of 32 patients. *Injury* 2007, 38, 365–370. [CrossRef]
11. Janssen, K.W.; Biert, J.; van Kampen, A. Treatment of distal tibial fractures: Plate versus nail: A retrospective outcome analysis of matched pairs of patients. *Int. Orthop.* 2007, 31, 709–714. [CrossRef] [PubMed]
12. Li, B.; Yang, Y.; Jiang, L.S. Plate fixation versus intramedullary nailing for displaced extra-articular distal tibia fractures: A system review. *Eur. J. Orthop. Surg.*

- Traumatol.* 2015, 25, 53–63. [CrossRef] [PubMed]
13. Marsh, J.L.; Bonar, S.; Nepola, J.V.; Decoster, T.A.; Hurwitz, S.R. Use of an articulated external fixator for fractures of the tibial plafond. *J. Bone Joint. Surg. Am.* 1995, 77, 1498–1509. [CrossRef] [PubMed]
 14. Nork, S.E.; Schwartz, A.K.; Agel, J.; Holt, S.K.; Schrick, J.L.; Winqvist, R.A. Intramedullary nailing of distal metaphyseal tibial fractures. *J. Bone Joint. Surg. Am.* 2005, 87, 1213–1221. [CrossRef] [PubMed]
 15. Sitnik, A.A.; Beletsky, A.V. Minimally invasive percutaneous plate fixation of tibia fractures: Results in 80 patients. *Clin. Orthop. Relat. Res.* 2013, 471, 2783–2789. [CrossRef] [PubMed]
 16. Fang, X.; Jiang, L.; Wang, Y.; Zhao, L. Treatment of Gustilo grade III tibial fractures with unreamed intramedullary nailing versus external fixator: A meta-analysis. *Med. Sci. Monit.* 2012, 18, Ra49–56. [CrossRef]
 17. Kerkhoffs, G.M.; Kuipers, M.M.; Marti, R.K.; Van der Werken, C. External fixation with standard AO-plates: Technique, indications, and results in 31 cases. *J. Orthop. Trauma* 2003, 17, 61–64. [CrossRef]
 18. Kloen, P. Supercutaneous plating: Use of a locking compression plate as an external fixator. *J. Orthop. Trauma* 2009, 23, 72–75. [CrossRef]
 19. Marti, R.K.; van der Werken, C. The AO-plate for external fixation in 12 cases. *Acta Orthop. Scand.* 1991, 62, 60–62. [CrossRef]
 20. Qiu, X.S.; Yuan, H.; Zheng, X.; Wang, J.F.; Xiong, J.; Chen, Y.X. Locking plate as a definitive external fixator for treating tibial fractures with compromised soft tissue envelop. *Arch. Orthop. Trauma Surg.* 2014, 134, 383–388. [CrossRef]
 21. Ma, C.H.; Wu, C.H.; Jiang, J.R.; Tu, Y.K.; Lin, T.S. Metaphyseal locking plate as an external fixator for open tibial fracture: Clinical outcomes and biomechanical assessment. *Injury* 2017, 48, 501–505. [CrossRef] [PubMed]
 22. Ma, C.H.; Tu, Y.K.; Yeh, J.H.; Yang, S.C.; Wu, C.H. Using external and internal locking plates in a two-stage protocol for treatment of segmental tibial fractures. *J. Trauma* 2011, 71, 614–619. [CrossRef]
 23. Zhang, J.; Ebraheim, N.; Li, M.; He, X.; Liu, J.; Zhu, L.; Yu, Y. External fixation using femoral less invasive stabilization system plate in tibial proximal metaphyseal fracture. *Clin. Orthop. Surg.* 2015, 7, 8–14. [CrossRef] [PubMed]
 24. Zhang, J.W.; Ebraheim, N.A.; Li, M.; He, X.F.; Schwind, J.; Zhu, L.M.; Yu, Y.H. Distal tibial fracture: An ideal indication for external fixation using locking plate. *Chin. J. Traumatol.* 2016, 19, 104–108. [CrossRef]
 25. Zhou, Y.; Wang, Y.; Liu, L.; Zhou, Z.; Cao, X. Locking compression plate as an external fixator in the treatment of closed distal tibial fractures. *Int. Orthop.* 2015, 39, 2227–2237. [CrossRef] [PubMed]
 26. Apivatthakakul, T.; Sananpanich, K. The locking compression plate as an external fixator for bone transport in the treatment of a large distal tibial defect: A case report. *Injury* 2007, 38, 1318–1325. [CrossRef]
 27. Ebraheim, N.A.; Carroll, T.; Hanna, M.; Zhang, J.; Liu, J. Staged treatment of proximal tibial fracture using external locking compression plate. *Orthop. Surg.* 2014, 6, 154–157. [CrossRef] [PubMed]
 28. Khatod, M.; Botte, M.J.; Hoyt, D.B.; Meyer, R.S.; Smith, J.M.; Akeson, W.H. Outcomes in open tibia fractures: Relationship between delay in treatment and infection. *J. Trauma* 2003, 55, 949–954. [CrossRef]
 29. Hidayat, L.; Triangga, A.F.R.; Cein, C.R.; Infantian, A.; Rahayu, B.F.P.; Resubun, A.P.; Magetsari, R. Low profile external fixation using locking compression plate as treatment option for management of soft tissue problem in open tibia fracture grade IIIA: A case series. *Int. J. Surg. Case Rep.* 2022, 93, 106882. [CrossRef]
 30. Ma, C.H.; Wu, C.H.; Tu, Y.K.; Lin, T.S. Metaphyseal locking plate as a definitive external fixator for treating open tibial fractures—clinical outcome and a finite element study. *Injury* 2013, 44, 1097–1101. [CrossRef]
 31. Zhang, J.; Ebraheim, N.A.; Li, M.; He, X.; Liu, J.; Zhu, L.; Yu, Y.; Siddiqui, S. External Fixation Using a Locking Plate: A Reliable Way in Treating Distal Tibial Fractures. *J. Orthop. Trauma* 2015, 29, e454–e458. [CrossRef] [PubMed]
 32. Tulner, S.A.; Strackee, S.D.; Kloen, P. Metaphyseal locking compression plate as an external fixator for the distal tibia. *Int. Orthop.* 2012, 36, 1923–1927. [CrossRef] [PubMed]
 33. Kanchanomai, C.; Phiphobmongkol, V. Biomechanical evaluation of fractured

- tibia externally fixed with an LCP. *J. Appl. Biomech.* 2012, 28, 587–592. [CrossRef] [PubMed]
34. Liu, W.; Yang, L.; Kong, X.; An, L.; Hong, G.; Guo, Z.; Zang, L. Stiffness of the locking compression plate as an external fixator for treating distal tibial fractures: A biomechanics study. *BMC Musculoskelet. Disord.* 2017, 18, 26. [CrossRef]
35. Zhang, J.; Ebraheim, N.; Li, M.; He, X.; Schwind, J.; Liu, J.; Zhu, L. External fixation using locking plate in distal tibial fracture: A finite element analysis. *Eur. J. Orthop. Surg. Traumatol.* 2015, 25, 1099–1104. [CrossRef]
36. Blažević, D.; Kodvanj, J.; Adamović, P.; Vidović, D.; Trobonjača, Z.; Sabalić, S. Comparison between external locking plate fixation and conventional external fixation for extraarticular proximal tibial fractures: A finite element analysis. *J. Orthop. Surg. Res.* 2022, 17, 16. [CrossRef]
37. Ang, B.F.H.; Chen, J.Y.; Yew, A.K.S.; Chua, S.K.; Chou, S.M.; Chia, S.L.; Koh, J.S.B.; Howe, T.S. Externalised locking compression plate as an alternative to the unilateral external fixator: A biomechanical comparative study of axial and torsional stiffness. *Bone Joint. Res.* 2017, 6, 216–223. [CrossRef] [PubMed]
38. Eckardt, H.; Morgenstern, M.; Cadosch, D.; Stoffel, K. Fluoroscopic Control of Tibial Torsion After Intramedullary Nailing: A Technical Trick. *J. Orthop. Trauma* 2021, 35, e507–e510. [CrossRef]
39. Dragomir-Daescu, D.; Op Den Buijs, J.; McEligot, S.; Dai, Y.; Entwistle, R.C.; Salas, C.; Melton, L.J., 3rd; Bennet, K.E.; Khosla, S.; Amin, S. Robust QCT/FEA models of proximal femur stiffness and fracture load during a sideways fall on the hip. *Ann. Biomed. Eng.* 2011, 39, 742–755. [CrossRef] [PubMed]
40. Perren, S.M. Physical and biological aspects of fracture healing with special reference to internal fixation. *Clin. Orthop. Relat. Res.* 1979, 138, 175–196.
41. Perren, S.M. Evolution of the internal fixation of long bone fractures. The scientific basis of biological internal fixation: Choosing a new balance between stability and biology. *J. Bone Joint. Surg. Br.* 2002, 84, 1093–1110. [CrossRef] [PubMed]
42. Possley, D.R.; Burns, T.C.; Stinner, D.J.; Murray, C.K.; Wenke, J.C.; Hsu, J.R. Temporary external fixation is safe in a combat environment. *J. Trauma* 2010, 69 (Suppl. 1), S135–S139. [CrossRef]
43. Moss, D.P.; Tejwani, N.C. Biomechanics of external fixation: A review of the literature. *Bull. NYU Hosp. Jt. Dis.* 2007, 65, 294–299.
44. Makelov, B.; Mischler, D.; Varga, P.; Apivatthakakul, T.; Fletcher, J.W.A.; Veselinov, D.; Berk, T.; Raykov, D.; Gueorguiev, B. Single-Stage Externalized Locked Plating for Treatment of Unstable Meta-Diaphyseal Tibial Fractures. *J. Clin. Med.* 2023, 12, 1600. <https://doi.org/10.3390/jcm12041600>
45. Schmal, H.; Strohm, P.C.; Jaeger, M.; Südkamp, N.P. Flexible fixation and fracture healing: Do locked plating ‘internal fixators’ resemble external fixators? *J. Orthop. Trauma* 2011, 25 (Suppl. 1), S15–S20. [CrossRef]
46. MacLeod, A.R.; Simpson, A.H.; Pankaj, P. Age-related optimization of screw placement for reduced loosening risk in locked plating. *J. Orthop. Res.* 2016, 34, 1856–1864. [CrossRef]
47. Ahmad, M.; Nanda, R.; Bajwa, A.S.; Candal-Couto, J.; Green, S.; Hui, A.C. Biomechanical testing of the locking compression plate: When does the distance between bone and implant significantly reduce construct stability? *Injury* 2007, 38, 358–364. [CrossRef]